

DR PARDEEP BAGEJA

M.B.B.S., D.N.B. (Orthopaedics), MNAMS, PLAB (U.K.)

Trauma & Arthroplasty Fellow

Birmingham and Solihull (NHS Foundation Trust), England

Senior Clinical Fellow (Knee, Ankle & Foot)

Luton & Dunstable (NHS Foundation Trust), England

Trauma Fellow

(National University Hospital) Singapore

SENIOR CONSULTANT ORTHO & JOINT REPLACEMENT SURGEON

CITY HOSPITAL (SIR GANGARAM HOSPITAL)

ADIVA HOSPITAL

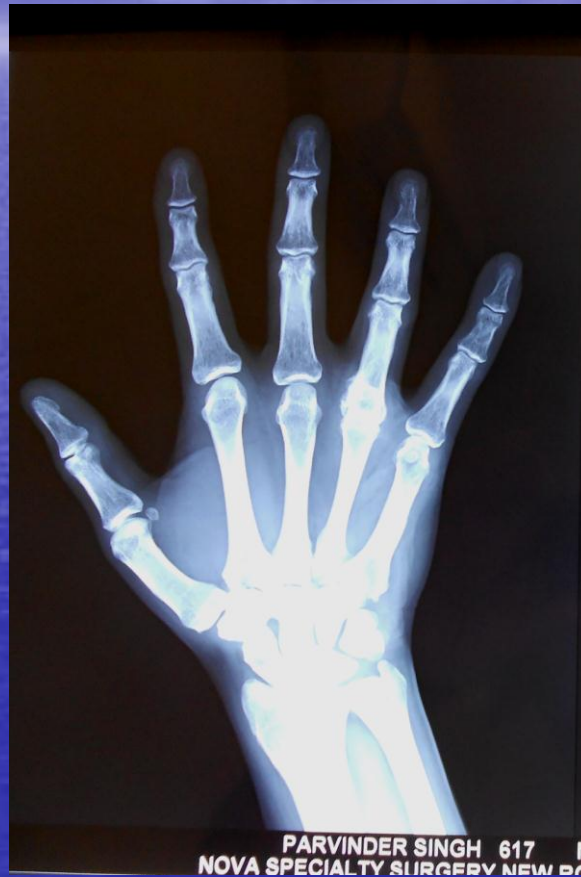CASE 1

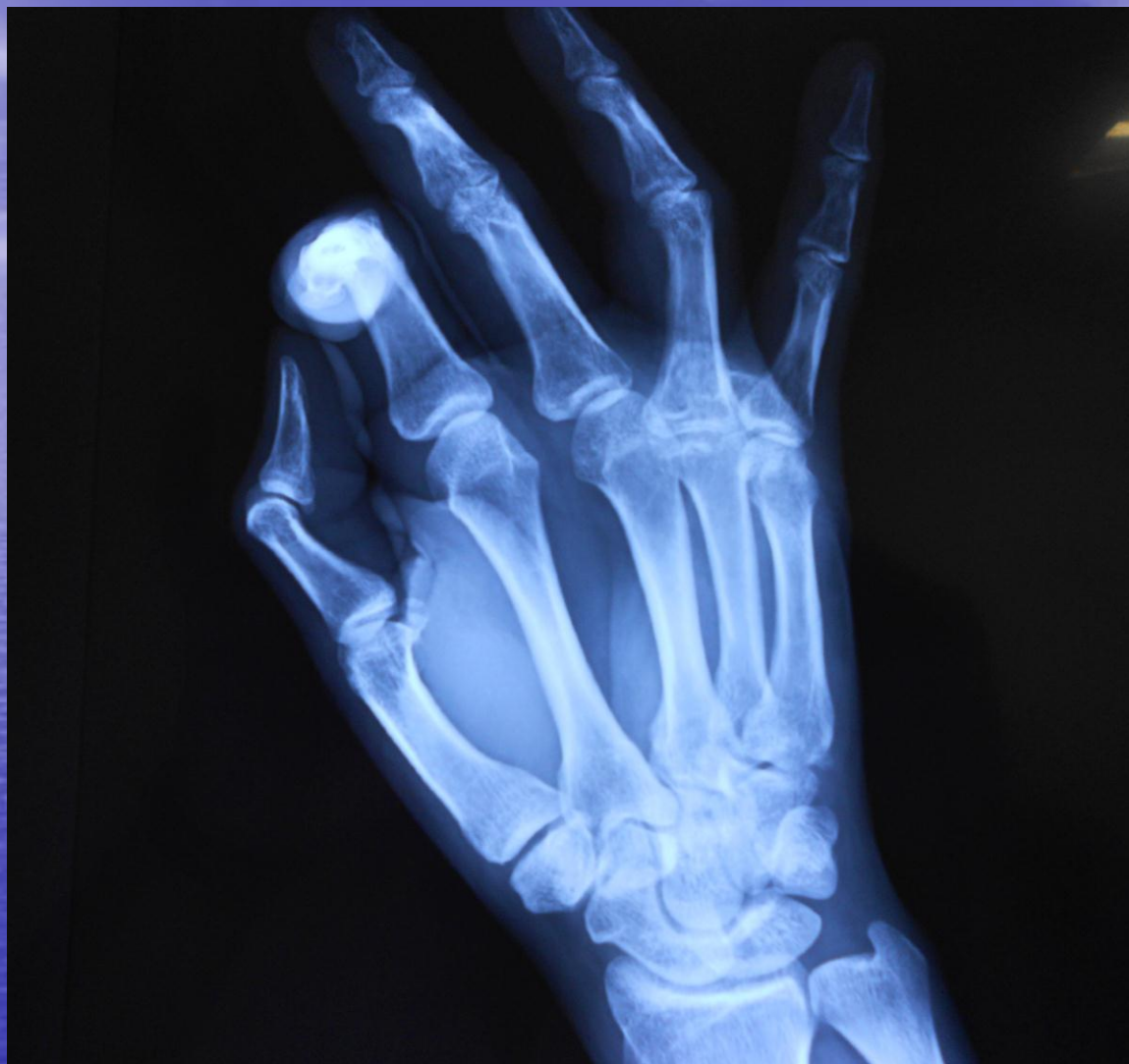- 45 YEARS MALE
- H/O SUSTAINED OPEN FRACTURE 4TH METACARPAL NECK.
- TREATED BY PLASTER AND SUTURING by LOCAL DOCTOR
- NOW DEVELOPED ARTHRITIS (4TH MP JOINT).

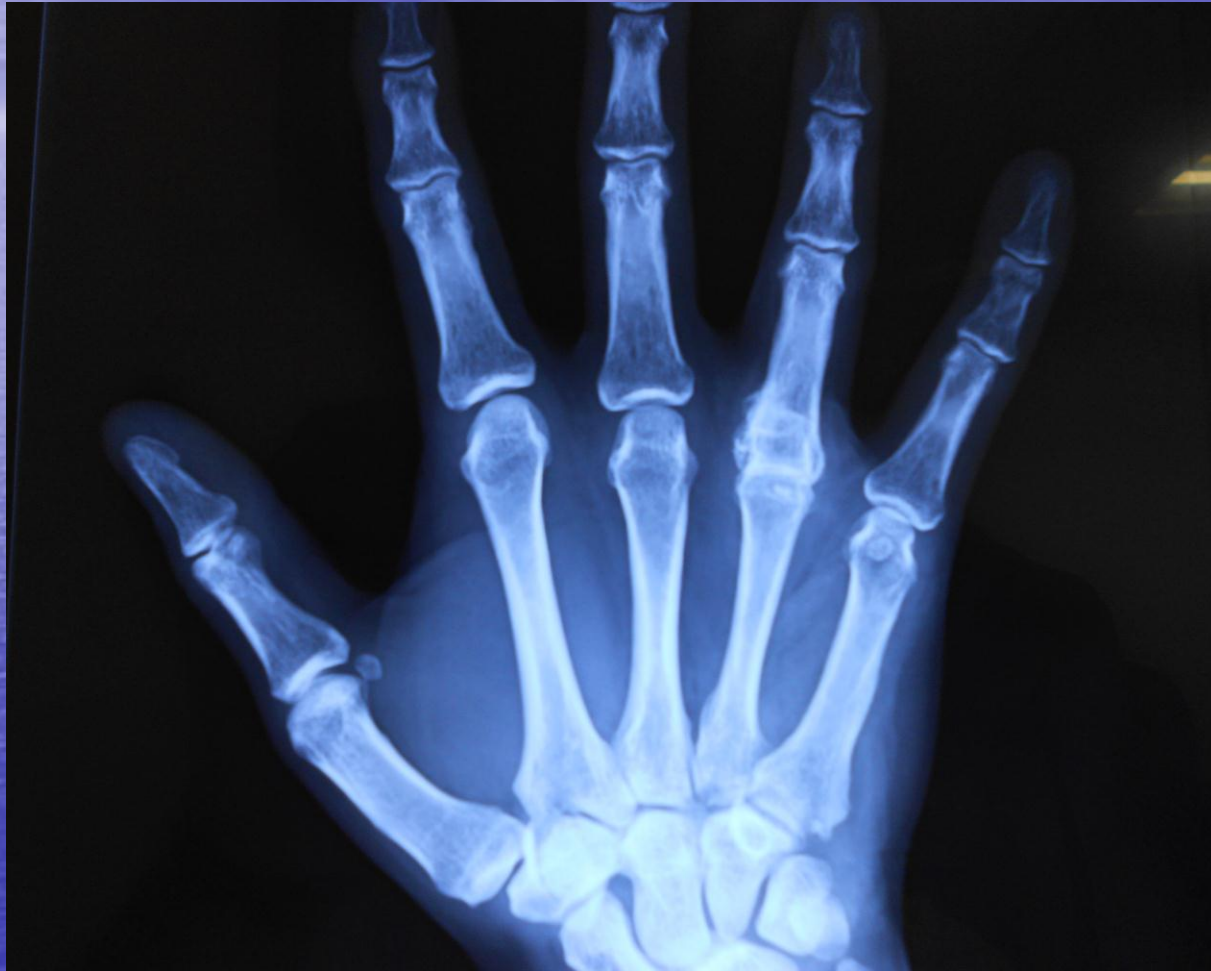MAIN COMPLAINTS ARE

- STIFFNESS OF THE MP JOINT
- PAIN ON AND OFF OCCASIONALLY

POST TRAUMATIC ARTHRITIS 4TH MP JOINT

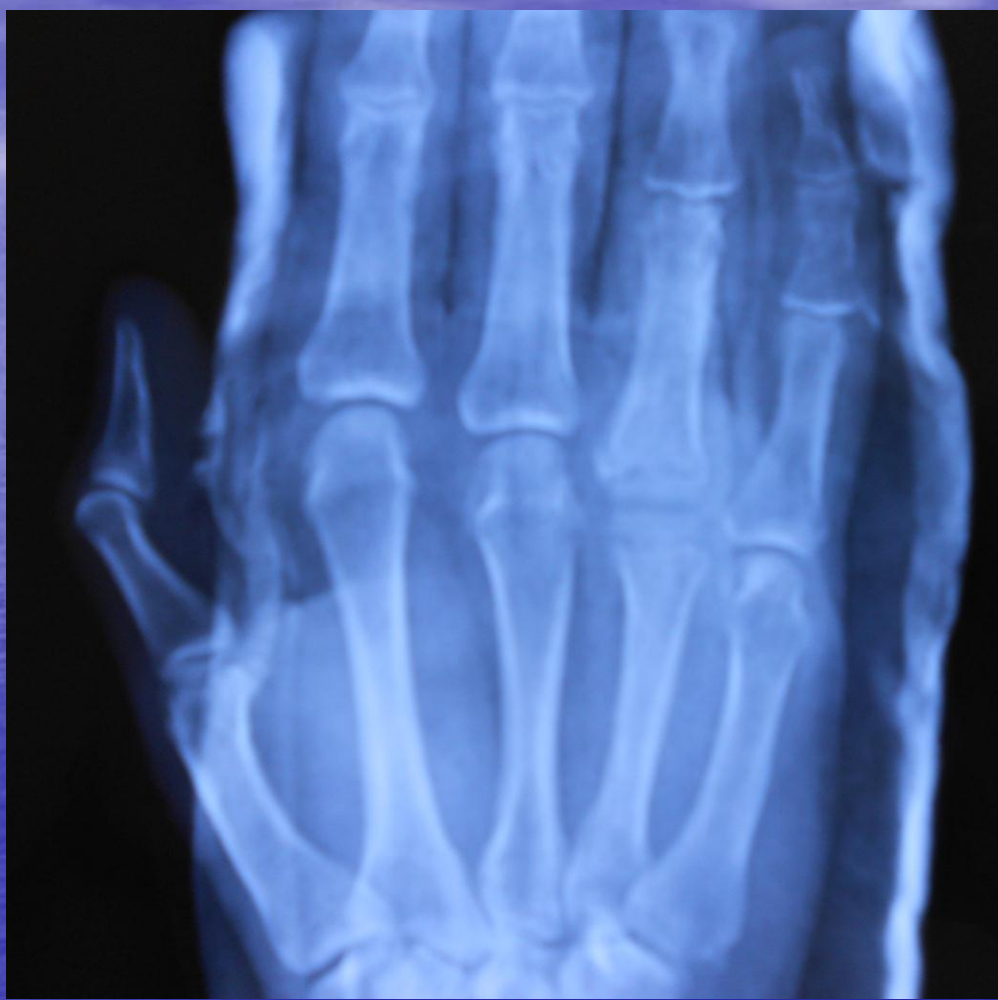


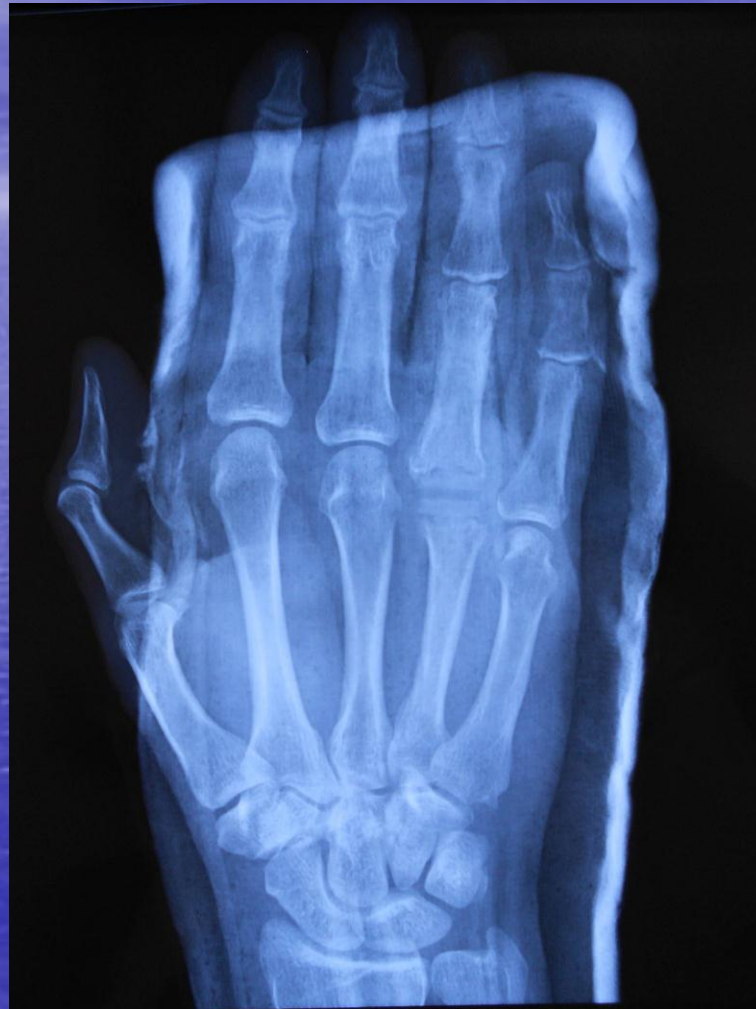

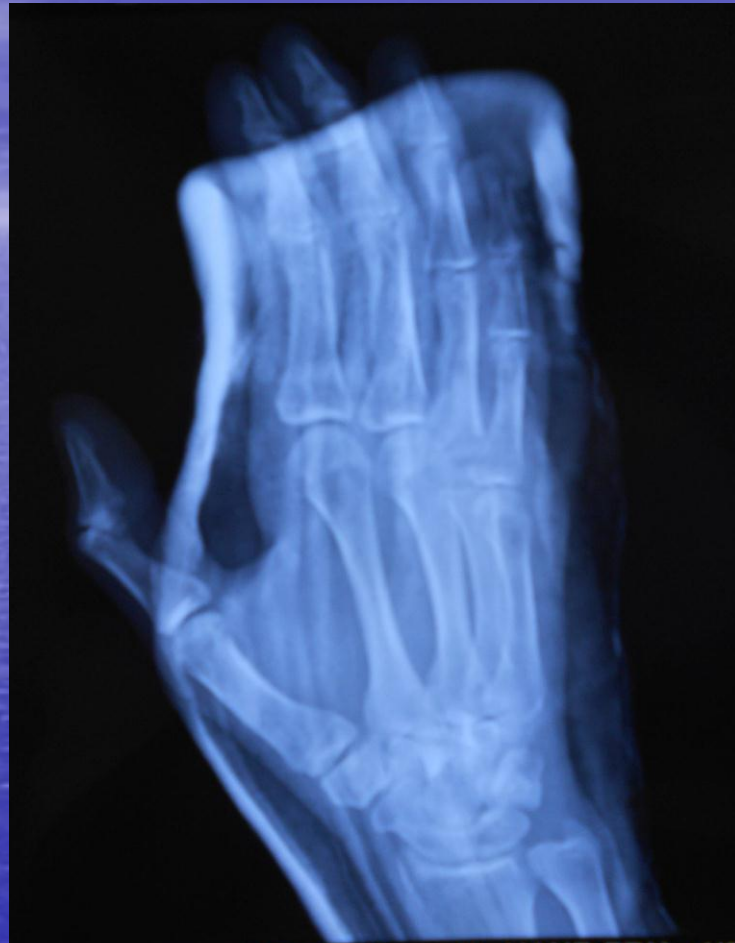


PLANNING

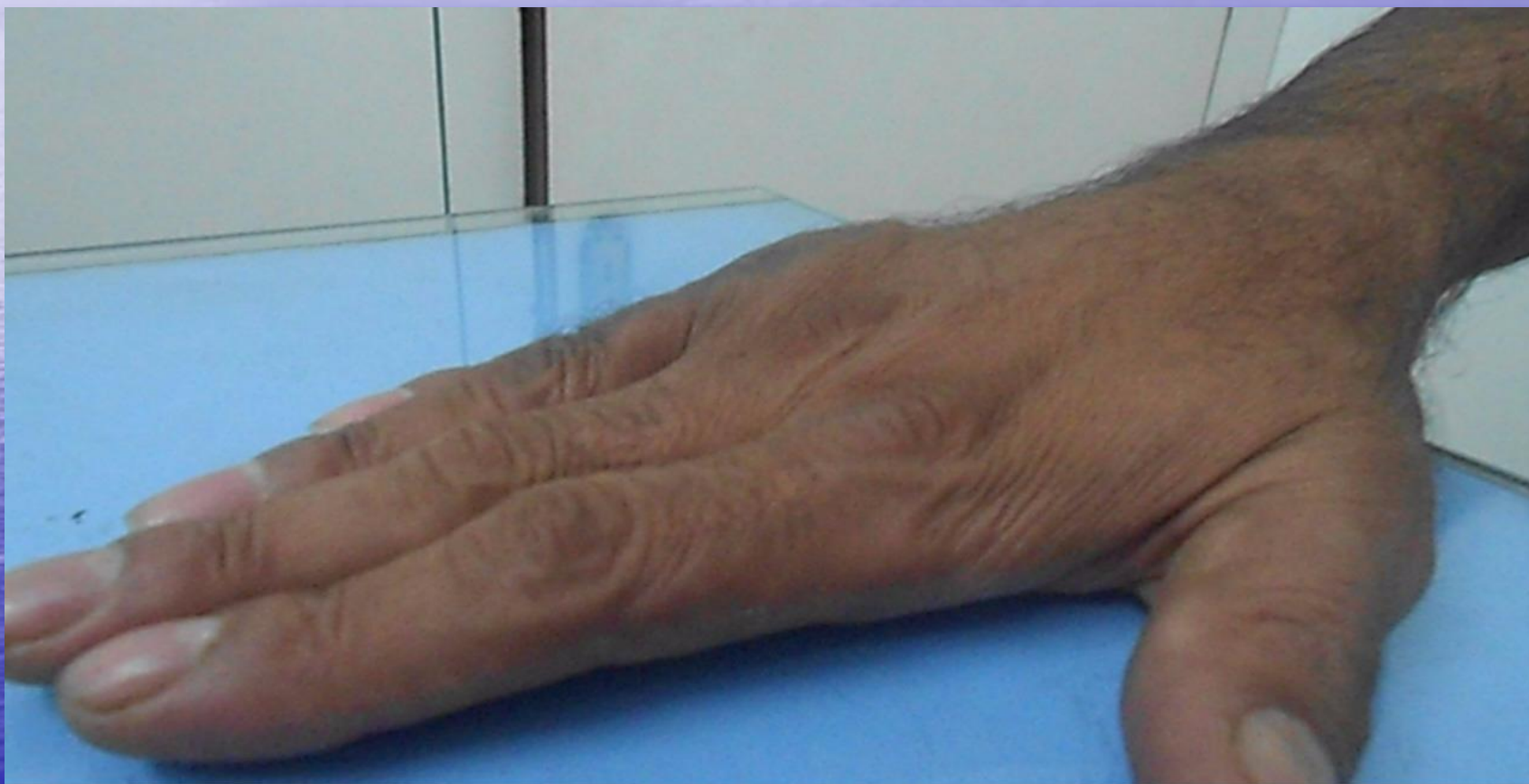- APPROACH TO THE JOINT (TOTAL MP JOINT REPLACEMENT)
- ASSISTED BY PLASTIC SURGEON.
- USED DEPUYS SILIASTIC IMPLANT , WITH 2 COMPONENTS ONE FOR PHALANX AND ONE FOR METACARPAL, (NONCEMENTED)







INDER SINGH 44YRS 619 M HAND,FRN 4/2







- 
- THANKS FOR PATIENCE HEARING